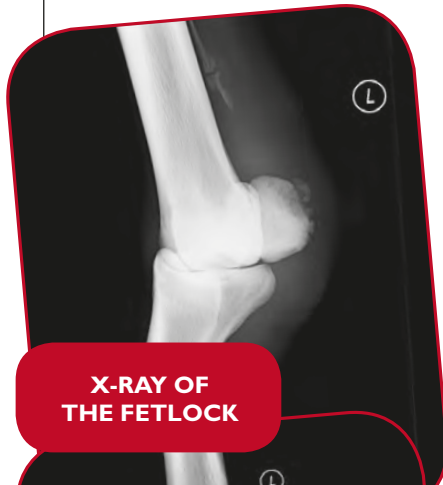
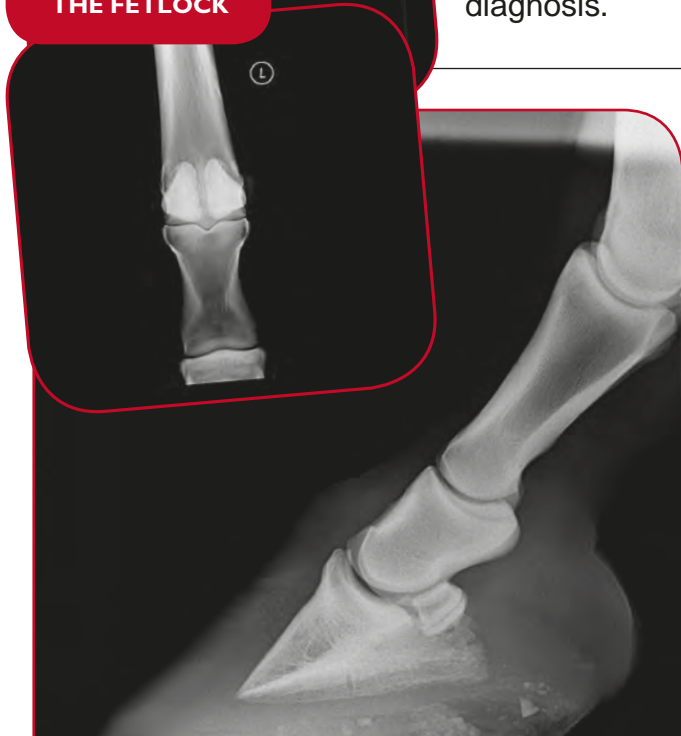
X-rays (Radiographs)




X-RAY OF THE FETLOCK



X-RAY OF THE FOOT & PASTERN

Radiographs – x-rays are taken by the veterinary surgeon to assist in diagnosing conditions relating to both the skeleton and soft tissues of the horse. Conventionally, x-rays have been taken using ionising radiation which is captured on a film. The varying densities of tissues in the patient absorb some of the radiation so the x-ray film is exposed to different degrees. The film is developed rather like traditional film camera processing to give a black and white image. Many modern systems now produce a digital image with no need for film. These images can be digitally manipulated to aid diagnosis.

RADIATION SAFETY



TAKING A FETLOCK X-RAY

Benefits of x-rays:

- excellent broad-ranging diagnostic tool;
- can be portable or used in clinics;
- provides a baseline status for monitoring development of disease or healing of injuries; useful add-on for pre-purchase vettings to highlight potential problems with feet and joints;
- newer digital systems produce images suitable for data transmission, such as email;
- measurements can be taken for diagnosis and monitoring of treatment.

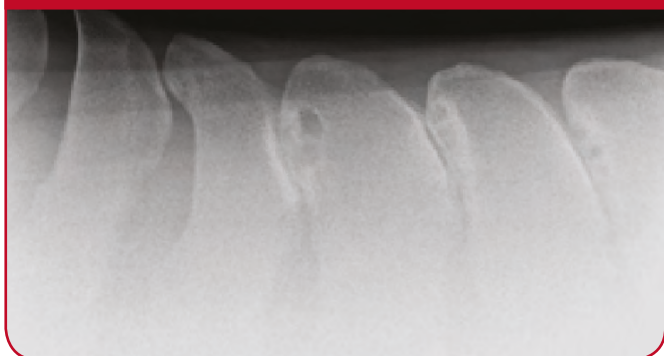
- Radiation can cause damage to tissues particularly those which have high activity such as the thyroid gland.
- Persons present will be restricted in number and must be over eighteen years of age.
- Pregnant women are strongly advised to avoid radiation exposure for the safety of the baby.
- All personnel must wear lead aprons, neck protectors and lead gloves.
- Radiography plates are held at arms length in a holder where possible.
- Sedation of the patient is often needed.

Many parts of the horse may be radiographed

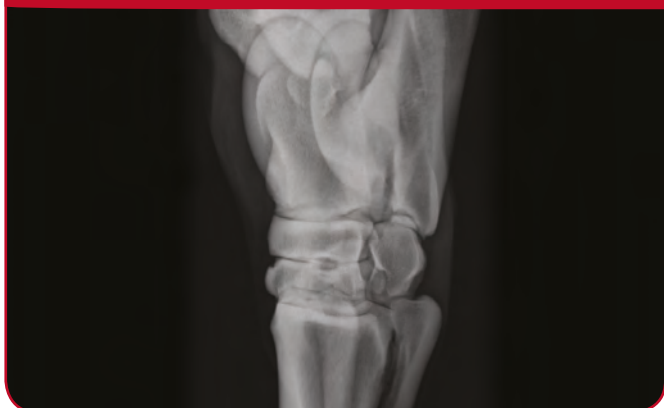X-RAYS OF THE TEETH CAN HELP TO DIAGNOSE DENTAL DISORDERS



'KISSING SPINES' OR OSTEOARTHRITIS MAY BE FOUND ON AN X-RAY OF THE BACK

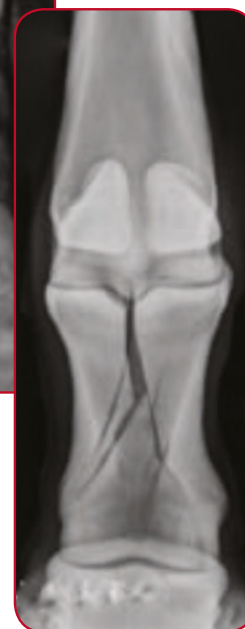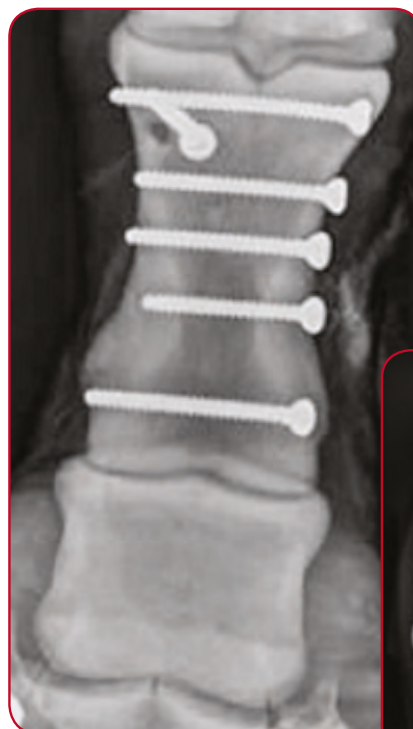


HOCK X-RAY: X-RAYS OF THE LIMBS ARE VERY USEFUL IN LAMENESS INVESTIGATIONS



COSTS

- There is a base cost for the procedure which covers the taking of the radiographs and interpretation by the vet.
- There is usually an incremental cost associated with additional plates.
- There may be further costs if the horse needs to be sedated for the procedure.



THESE RADIOGRAPHS SHOW HOW A SERIOUS FRACTURE HAS BEEN SUCCESSFULLY FIXED USING SCREWS



XLEquine is a novel and exciting initiative conceived from within the veterinary profession made up of independently owned, progressive veterinary practices located throughout the United Kingdom, members of XLEquine are committed to working together for the benefit of all their clients.
© XLVet UK Ltd.

No part of this publication may be reproduced without prior permission of the publisher.

For further information contact your local XLEquine practice:

www.xlequine.co.uk

Go to www.xlequine.co.uk