

Tooth Extraction

Dental problems such as tooth root abscesses, fractured teeth and periodontal disease will commonly require dental extraction as part of the treatment protocol.

Dental extraction can be a time consuming and difficult process (even when the teeth feel loose!) and requires a wide range of surgical equipment. Dental extraction should only be carried out by a veterinary surgeon with experience in dental surgery.



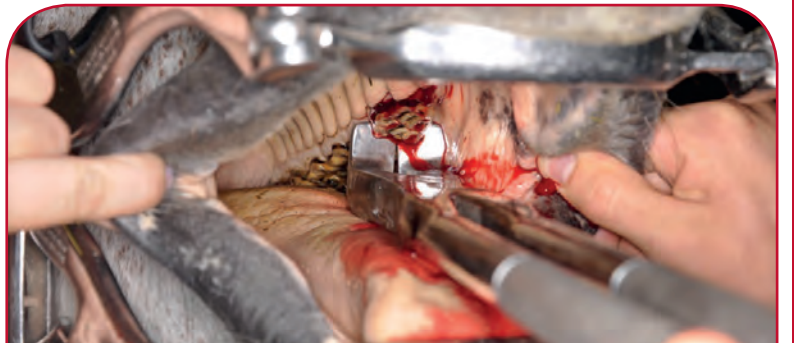
1. Oral tooth extraction

Oral extraction whilst the horse is standing is the preferred method of tooth removal. There are fewer complications compared with surgical repulsion. Unfortunately oral extraction is not possible in all diseased teeth. It may not be possible to orally extract teeth with fractures and dental decay. Some teeth may fracture during oral extraction and require surgical repulsion to complete the procedure.

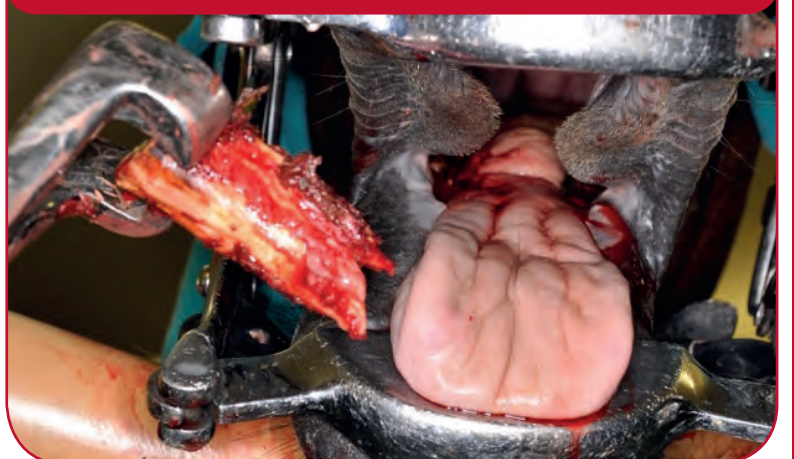
Horse's molar or cheek teeth can be up to 10cm in length with a large and extremely strong periodontal ligament holding the tooth within the jaw bone. Oral extraction often requires time and patience! Extraction is carried out under heavy sedation, often with the use of dental nerve blocks and pain killers.

Once the correct tooth is identified, the gum margin is separated from the tooth edge using dental elevators and forceps are applied to the tooth. A gentle rocking action is applied to the tooth for a prolonged period (this is often several hours) to loosen the tooth and breakdown the periodontal ligament. Once sufficiently loose the tooth can be gently but firmly elevated out of the tooth socket.

The remaining socket may be packed with impression material or left to granulate.



ORAL EXTRACTION OF A CHEEK TOOTH





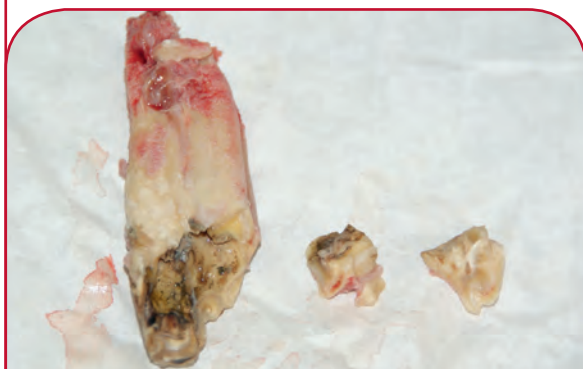2. Surgical tooth extraction

If the identified diseased tooth is not amenable to oral extraction, then there are a number of surgical options available to your veterinary surgeon. Most of these require general anaesthesia.

Dental repulsion is the most common surgical technique. After surgical incision over the diseased tooth roots, the tooth is punched out from the root into the oral cavity using a metal punch and surgical mallet. This requires careful intra-operative x-rays to ensure the correct positioning of the instruments. This method will lead to the destruction of the tooth root and post-operative radiographs are required to ensure complete removal.

The roots of the back four upper cheek teeth may sit within the sinuses of the head of the horse. If these become infected they often cause a sinusitis with purulent nasal discharge, often with a pungent smell. Repulsion of these teeth requires exposure of their roots by flapping open the sinus cavity.

Recovery and aftercare of the patient is more involved than that following oral extraction.



FRAGMENTED MOLAR TOOTH FOLLOWING REMOVAL BY DENTAL REPULSION

SIGNS OF A DISEASED TOOTH

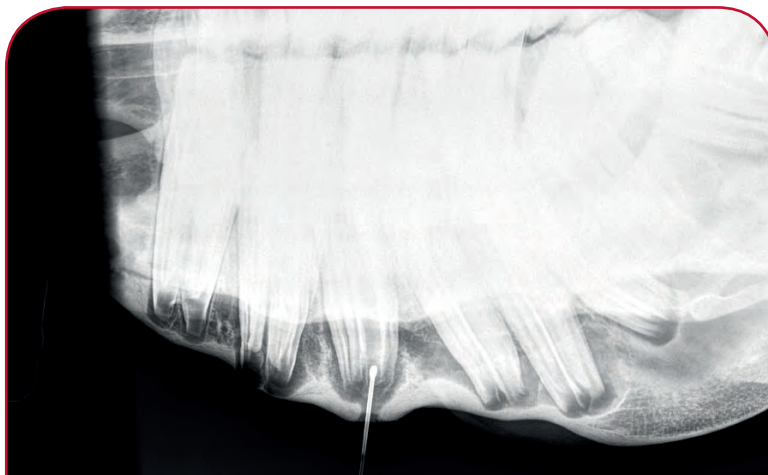Some horses with diseased teeth may show no clinical symptoms and may only be detected at a routine dental check up. Signs that may be seen include:

- dropping food (quidding)
- weight loss
- bad odour from mouth
- head tilt or shaking
- facial swelling (possible abscess)
- nasal discharge.

DECISION TO REMOVE TEETH

As dental extraction can be time consuming, costly and not without potential complications, careful assessment must be made by your veterinary surgeon to establish the need for extraction and ensure the correct tooth is removed.

Thorough oral examination, using sedation, head stand, dental headlight, dental mirrors and picks will help identify any evidence of diseased teeth. Dental radiography can identify diseased teeth including root abscesses.



X-RAY OF LOWER MOLAR ABSCESS WITH PROBE INSERTED INTO TRACT TO HIGHLIGHT THE AFFECTED TOOTH



XLEquine is a novel and exciting initiative conceived from within the veterinary profession made up of independently owned, progressive veterinary practices located throughout the United Kingdom, members of XLEquine are committed to working together for the benefit of all their clients.
© XLVet UK Ltd.

No part of this publication may be reproduced without prior permission of the publisher.

For further information contact your local XLEquine practice:

www.xlequine.co.uk

Go to www.xlequine.co.uk